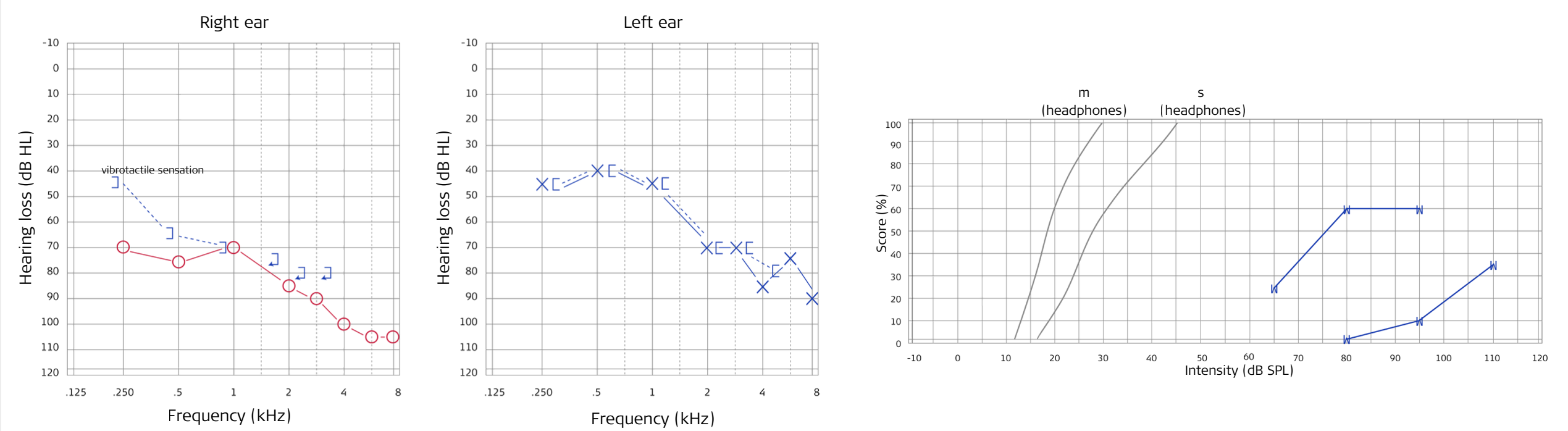


# Patient case: Machinist with severe sensorineural noise-induced hearing loss



## 1 Preoperative audiogram



## 2 Patient

- Male, 55 years old
- Machinist
- Progressive bilateral sensorineural hearing loss
- Hearing aid user for many years
- Recurrent sudden hearing loss on right ear
- No signs of central pathogenesis

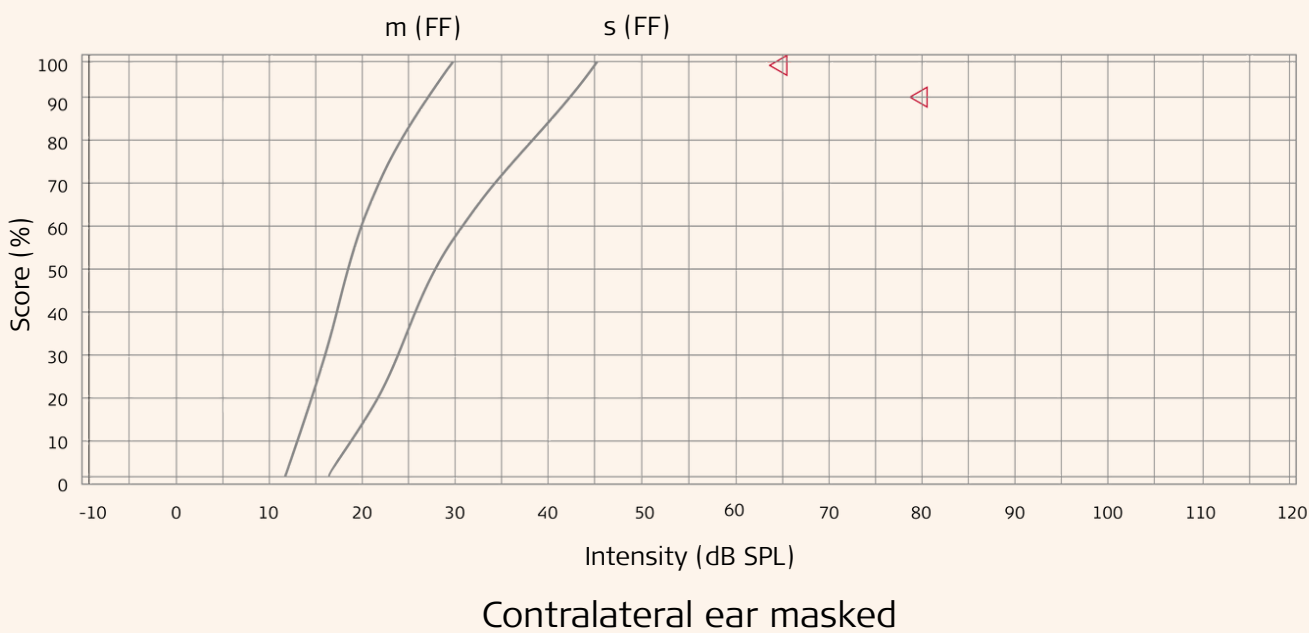
## 3 So far

- Bilateral hearing aids
- Insufficient speech understanding after last sudden hearing loss

## 4 Treatment: Cochlear implant in right ear

- Round window approach
- Synchrony Pin, Flex 28 electrode
- RONDO 3 audio processor

### Speech audiogram 12 months postoperative with CI



Indication criteria CI and pure tone audiogram of untreated patient

